



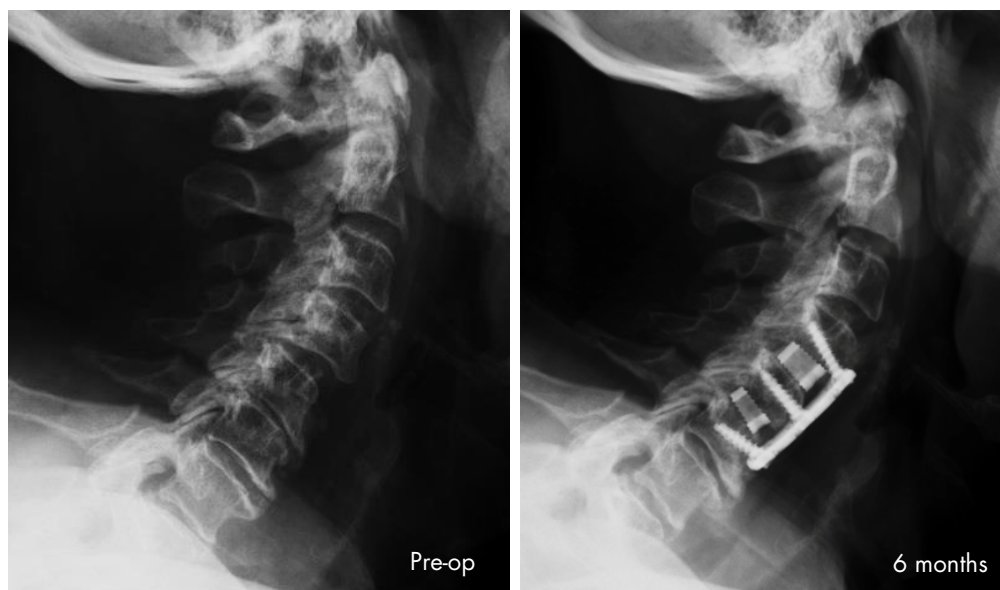
## Two-level ACDF Using Silicon Nitride Implants in a Case of Quickly Progressing Loss of Deltoid Strength

Graham Calvert, M.D.

Mississippi Sports Medicine and Orthopaedic Center

### SUMMARY

A 77-year-old male with radiating neck pain and a severely weak shoulder, underwent two-level anterior cervical discectomy and fusion (ACDF) using silicon nitride implants. Patient experienced complete pain resolution and steadily improved shoulder strength, with fusion at 6 months postoperatively.



One-year postoperative lateral radiograph demonstrates excellent implant position and fully fused C4-6

### DIAGNOSIS & PROCEDURE

Patient presented with a 3-month history of neck pain that radiated into right shoulder. After a failed subacromial injection, he experienced rapid and progressive loss of strength in right shoulder. Examination of bilateral upper extremities and bilateral lower extremities revealed flaccid to 0/5 deltoid and 4/5 biceps on the right; otherwise he had 5/5 motors in all other upper and lower extremities.

MRI indicated severe C4-5 and C5-6 spondylosis with foraminal stenosis and C4-C5 spondylolisthesis. EMG exposed significant right C5 pathology in the form of a radiculopathy.

Patient was diagnosed with C4-C5 spondylolisthesis with spondylosis and bilateral neuroforaminal stenosis and right C5 palsy. Additionally, he had C5-C6 spondylosis with severe neuroforaminal stenosis.

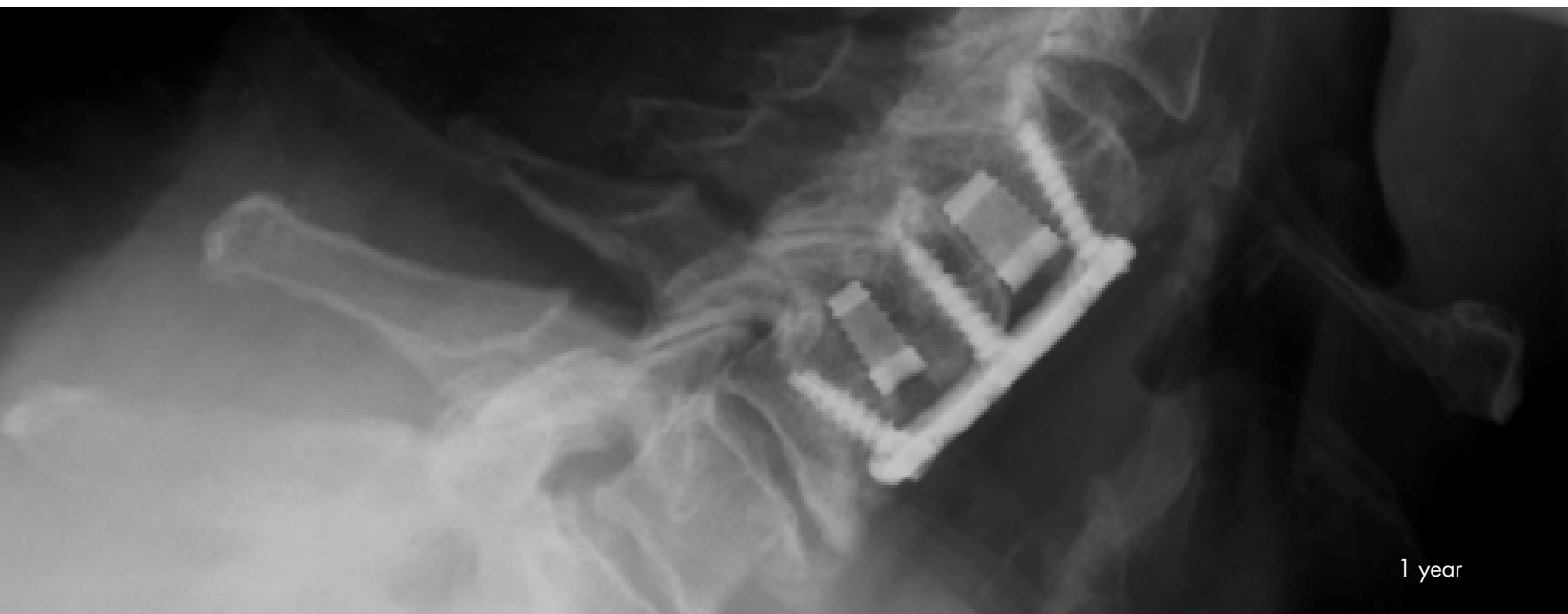
Quick surgical intervention was administered to increase patient's chance of regaining strength. Patient underwent an ACDF at C4-5 and C5-6 using silicon nitride interbody fusion devices (**Amedica Valeo™ II C** – 14x12mm footprint, 8mm height, 6° lordosis at C4-5, and 14x12mm footprint, 6mm height, 6° lordosis at C5-6), packed with DBM putty and local autograft. Plate and screws were used for anterior fixation.

## RESULTS

---

At 6-weeks postoperative, patient's neck and shoulder pain had resolved and right shoulder weakness was improving. At 3-months postoperative, aside from some mild dysphagia, patient's pain remained resolved and shoulder strength showed progressive improvement. At 6-months postoperative, patient had significantly stronger deltoid and continued with neck and shoulder physical therapy.

Radiographs evaluated at 6-weeks, 3-months, and 6-months postoperative demonstrated intact hardware, good implant positioning, and progressive fusion. One-year follow-up confirmed successful surgery and fully fused C4-6.



## CONCLUSION

---

- Excellent outcome with a two-level ACDF using silicon nitride interbody devices
- Quick resolution of pain and weakness at 6-weeks post-op
- Great patient satisfaction and fully fused C4-6 at 1-year follow-up using **Amedica Valeo™ II C interbody cages**