

Clinical Experience with AxoGuard® Nerve Protector in Revision Carpal Tunnel Syndrome

Dean Sotereanos, MD, Department of Orthopedic Surgery, Allegheny General Hospital, Pittsburgh, PA

Introduction

Chronic nerve compression is one of the most common forms of peripheral nerve injury. Although surgical decompression is successful in most cases, a significant number of patients (14 to 32%) do not experience satisfactory results from the primary release alone.¹ Poor outcomes have been linked to scar tissue formation within the nerve and/or adhesions between the nerve and surrounding tissues.^{2,3} A revision procedure is often required to alleviate the symptoms, and a nerve wrap can be used for providing protection for the nerve and minimizing the risk of cicatrix formation to nerve.^{4,5,6}

In this case, the patient had experienced two previous failed carpal tunnel releases and presented with symptoms of recurrent carpal tunnel. Surgery was indicated after physical examination and confirmation of recurrent carpal tunnel syndrome with electromyography. Note that the following is only an example of a surgical technique for wrapping the median nerve for treatment of recurrent carpal tunnel syndrome. The methods described here may be adapted by the surgeon to fit the specific case being treated.

Surgical Method

Nerve exposure and assessment

1. Procedures were performed with the patient under general anesthesia and under tourniquet. Skin and superficial soft tissues were dissected in the distal forearm. The median nerve was exposed proximally, starting with undamaged tissue, and then identified through the carpal canal.
2. Scar tissue surrounding the nerve was dissected. Complete neurolysis was performed, starting from the normal portion of the nerve and then extending through the carpal tunnel, under loupe magnification or microscope. A large degree of swelling was noted (the nerve was approximately 8mm in diameter).
3. The fascicles comprising the digital nerves and the motor branch to the thenar eminence were identified. Scarring was identified between fascicles; therefore, internal neurolysis was performed at the branch juncture. Completed nerve exposure is shown in Figure 1.

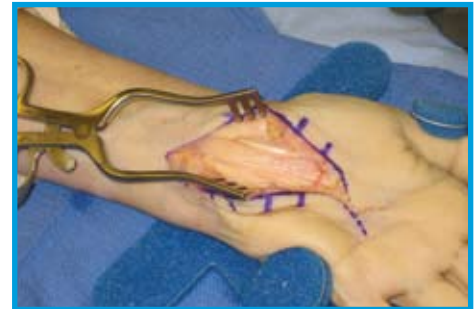

Figure 1. Nerve release and exposure. Scar tissue surrounding the nerve was dissected, starting proximally with undamaged tissue. Internal neurolysis was performed at the juncture of nerve branches on the distal side to release scarring between fascicles

Implantation of the AxoGuard® Nerve Protector

4. The appropriate size AxoGuard® Nerve Protector was selected based on the diameter of the patient's nerve and the length of the affected area. Care should be taken to select a diameter that will not constrict or compress the nerve. In this case, the nerve was approximately 8mm in diameter, and there was a 40mm length of damaged nerve tissue. Therefore, the 10x40 (ID x length) was selected.
5. AxoGuard® Nerve Protector was prepared by first peeling open the Tyvek® pouch and passing the tray into the sterile field. The product was hydrated in the pre-molded hydration reservoir of the packaging tray. Product was hydrated just prior to implantation in sterile saline to best suit the surgeon handling preference, (Figure 2).



Figure 2. Hydration of AxoGuard® in pre-molded hydration reservoir prior to implantation.

Implantation of the AxoGuard® Nerve Protector

6. AxoGuard® Nerve Protector was unrolled into a sheet and inserted under the nerve. The longitudinal edges of the product were aligned on the medial side of the nerve. Interrupted sutures (8-0 Prolene with cutting needle) were used to maintain closure of the longitudinal slit (Figure 3).

7. One stitch through the AxoGuard® Nerve Protector and adjacent soft tissue was used to prevent migration (Figure 4).

8. Upon completion of the procedure (Figure 5), the tourniquet was released, hemostasis was achieved, and the incision was closed.

Feedback on Intra-operative Handling / Conclusions

The AxoGuard® Nerve Protector is an off-the-shelf option for protecting peripheral nerves after nerve compression to minimize the risk of soft tissue attachments. The AxoGuard® Nerve Protector has excellent handling properties and is technically feasible for use in a revision carpal tunnel nerve release procedure. The AxoGuard® Nerve Protector has the following features:

- Semi-translucent, allowing visualization of the nerve
- Conformable to nerve for a custom fit
- Well-suited for confined spaces to allow nerve gliding
- Easily positioned and sutured

References

1. Haupt et al., 1993. J Hand Surg Br 18(4):471-474.
2. Stutz et al., 2006. J Hand Surg Br 31(1):68-71.
3. Tung and Mackinnon, 2001. Plast Reconstr Surg 107(7):1830-1843.
4. Strickland et al., 1996. J Hand Surg Am 21(5):840-848.
5. Varitimidis et al., 2000. J Hand Surg Br 25(3):271-275.
6. Xu, et al., 2000. J Hand Surg [Am] 25(1):93-103

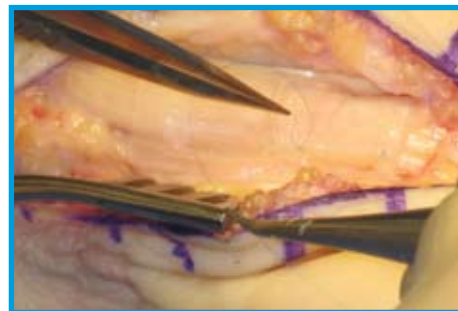


Figure 3. Placement of AxoGuard® Nerve Protector and closure of longitudinal slit. The hydrated product was wrapped around the nerve, and the longitudinal edges were aligned. Interrupted sutures were used to maintain closure of the longitudinal slit.

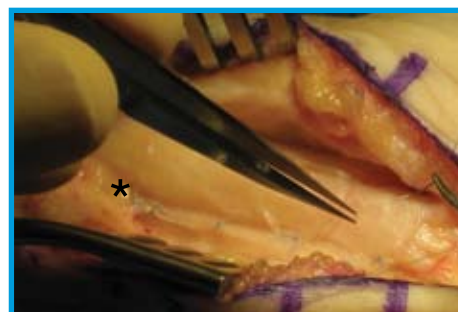


Figure 4. One stitch was inserted through the AxoGuard® Nerve Protector and adjacent soft tissue to prevent migration of the nerve wrap (denoted with *).

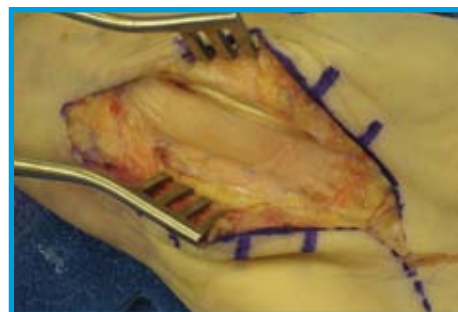

Figure 5. Completed implantation of AxoGuard® Nerve Protector.

For additional information on



Contact:

AxoGen, Inc.

Tel: 1-888-296-4361

Email: Customerservice@AxoGenInc.com

Website: www.axogeninc.com